

# Kyphotic deformity in pott's spine

**Paudel S**

Sushil Paudel, Teaching Assistant, Department of Orthopaedics, Tribhuvan University Teaching Hospital, Kathmandu, Nepal

## ABSTRACT

Kyphotic deformity is a well-known complication in spinal tuberculosis patients. This deformity, which is seen in 15% of patients treated conservatively, progresses in two phases: Phase I, which includes the changes in the active phase, and Phase II, which includes changes after the disease is cured. Factors influencing deformity progression are severity of the angle before treatment, the level of the lesion, and age of the patient. Adults have an increase less than 30° during the active phase with no additional changes in the healed phase. During the growth spurt of the children, there is worsening of the deformity in 39% (Type I), an improvement in 44% (Type II), and no change in 17% (Type III). Spine-at risk radiologic signs aid in early identification of the children at risk of late progressive deformity. Surgery for preventing deformity must be done earlier rather than later and in patients with severe disease.

**Key words:** Kyphosis, Pott's spine

## INTRODUCTION

Uncomplicated spinal tuberculosis is largely a medical disease due to effective antitubercular chemotherapy<sup>1</sup>. More than 80% of patients with spinal tuberculosis have some sort of detectable kyphosis at the time of presentation<sup>2</sup>. Patients treated conservatively have an average increase of 15° in deformity<sup>1,3</sup> and three to five percent of the patients end up with a deformity greater than 60°. Severe kyphosis is cosmetically unappealing, functionally disabling, and can lead to late-onset paraplegia. Prevention of deformity should be an essential aspect of any treatment schedule in spinal tuberculosis as correction of established deformity is difficult and hazardous<sup>4</sup>.

## BODY

### The Natural History and factors influencing the deformity

Spinal tuberculosis affects the anterior structures of the vertebral column and intervening discs in more than 90% of patients<sup>1</sup>. Although chemotherapy inactivates the disease process, vertebrae collapse and destruction of discs continue until the healthy vertebral bodies in the region of the kyphosis meet anteriorly and consolidate. In severe disease with complete destruction of entire vertebral segments, the superior healthy vertebra rotates and descends so that its anterior surface comes into contact with the superior surface of the inferior healthy vertebra<sup>5,6</sup>. In a longitudinal study of 15 years, Rajasekaran found that the deformity progresses in two distinct phases: Phase I (active phase), which included the changes in the first 18 months during the period of activity and Phase II (healed phase) that occurred after the disease was healed. Adults had a lesser deformity at presentation, lesser increase of deformity during Phase I, and virtually no change after disease healed. The progression of deformity usually was less than 30° and restricted to the first 12 to 18 months when consolidation of the focus was complete. Children had a higher degree of deformity at presentation, a greater tendency for collapse during the active phase of the disease, and continued and variable progression even after the disease was cured and growth was completed<sup>7,8</sup>.

### Address for Correspondence:

Dr. Sushil Paudel  
Teaching Assistant  
Department of Orthopaedics  
Tribhuvan University Teaching Hospital, Kathmandu,  
Nepal  
E-mail: paudelsusil@gmail.com

Increased severity of destruction at presentation, increased flexibility of the spine in children, variable destruction of the growth plates interfering with future growth, and the suppressive effect of the mechanical forces of kyphosis on the growth of the anterior half of the fusion mass and adjacent healthy vertebrae are few reasons postulated for the increased susceptibility of children to kyphosis<sup>9</sup>. During Phase II, there is an increase in deformity in 39% of the children and no change in deformity in 17% of children<sup>7</sup>. Five distinct types of progress are seen during the growth phase<sup>7</sup>. Type I progression shows continued progress through the entire period of growth. This increase could occur continuously after Phase I or after three to six years after the disease was cured. In type I, the increase in deformity is maximal. Type II progression shows beneficial effects during growth with a decrease in deformity after healing of the disease. This can occur immediately after Phase I (Type IIA) or after three to six years (Type IIB). Children with Type IIA progression have the best outcome because they have a lesser increase during Phase I, and a greater improvement during Phase II. In Type III progression, children have a minimal disease with no major destruction of the vertebral bodies without any major change in the deformity during Phase I and Phase II<sup>7-9</sup>.

The severity of deformity depends on the extent of destruction, the age of the patient, and the level of lesion<sup>6</sup>.

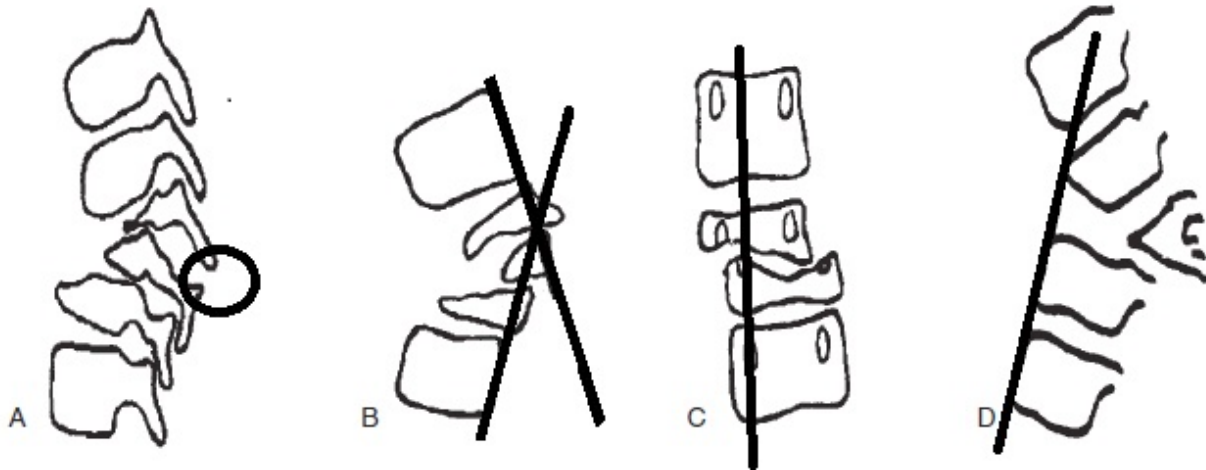
The extent of deformity at presentation, the amount of collapse in the first 18 months, and the progression in children during growth differ in different regions of the spine<sup>7</sup>. Puig Guri<sup>10</sup> explained that the collapse in tuberculous spine occur by flexion in the sagittal plane of one spinal segment on the other (in flexion) or along a longitudinal axis (telescoping). In the lumbar region, because of the large size of the disc, the vertical position of the articular facets and the relative narrowness of the pedicle, a marked amount of telescoping is possible. In the thoracic spine, because of the more horizontal orientation of the articular facets, destruction of the anterior structures leads to subluxation and ultimately an angulatory collapse<sup>10</sup>. Patients with dorsal lesions have the highest deformity at the time of presentation, but this could be attributable to the additive effect of the normal kyphosis, which ranges from 20° to 40°. However, the rib cage offers protection against additional collapse because the progress during the period of growth is less compared with growth in patients with dorsolumbar

lesions. Patients with dorsolumbar lesions have the worst prognosis because of a greater collapse during the active phase and a greater deterioration in children during the growth period. Patients with lumbar lesions have the best prognosis with the least deformity at presentation, a lesser increase during the active phase, and also a tendency for substantial decrease during the growth period in children<sup>7-9</sup>.

The angle of deformity at the start of treatment and at 18 months has a poor correlation to the number of vertebral bodies involved because of variation in the extent of destruction in each vertebral body and patients<sup>7</sup>. However, the vertebral body loss at the start of treatment has a good correlation with the severe deformity at the five year follow-up. It is reported that the deformity at five years can be predicted with the application of the formula  $Y = a + bX$ , where Y is the deformity at five-year follow-up, X is the pre-treatment vertebral body loss, and a and b are constant values of 5.5 and 30.5<sup>11</sup>. There is an average kyphosis angle of 30° to 35° for the complete destruction of each vertebral body in the dorsal and dorsolumbar region and approximately 20° for the complete loss of each vertebral body in the lumbar region. This correlation is not maintained in children at 10 years follow-up because children have a continued and variable progress in deformity even after the disease resolves, until the entire potential for growth is completed<sup>3</sup>.

#### **Intervention for Prevention of Deformity in Spinal Tuberculosis: Indications and Surgery**

In adults, the final deformity has a good correlation to the pre-treatment vertebral loss; and a loss of 0.75 in the dorsal and dorsolumbar regions and 1.0 in lumbar region is an indication for surgery. In children, the changes during the growth period are more important than changes during the active period of the disease and determine the progress of deformity. Children prone for such late progressive collapse can be identified even during the early stages by the presence of spine-at-risk radiologic signs<sup>9</sup>. Four radiologic signs are described to indicate the presence of such instability<sup>7,9</sup> (Figure 1). Each of these signs is given a score of one with a maximum score of four. A spinal instability score of more than two is associated with a significantly higher increase in the final deformity. These signs are useful clinically because they occur early in the course of the disease and preventive surgery for progressive collapse can be advised.



**Figure 1:** Four spine-at-risk radiologic signs: (A) The facet dislocation, (B) The posterior retropulsion of the diseased vertebra, (C) Lateral translation, and (D) The line drawn along the anterior surface of the lower normal vertebra intersects the inferior surface of the upper normal vertebra. Toppling has occurred when the line intersects above the middle of the anterior surface of the upper vertebra. (Redrawn with modifications from: Rajasekaran S et al<sup>9</sup>.)

Posterior fusion surgery as an isolated procedure is of historical importance because of its high failure rate<sup>12</sup>. The necessity of stabilization by anterior strut bone grafts was proven conclusively in the random trials conducted by the Medical Research Council in Hong Kong<sup>12-14</sup>. The good results obtained by the Hong Kong group have not been achieved universally<sup>8,15</sup>. Bailey et al<sup>15</sup> reported an increase in deformity in 72 patients out of 100 treated by anterior arthrodesis. In 42 patients, the increase was more than 10° (range, 11°–106°), the average increase being 22.2°. In an eight-year follow-up of 81 patients treated by anterior surgery, Rajasekaran<sup>8</sup> found the deformity progressed in 42% of patients. The poor results mainly were attributable to failure of the graft, which could be by slippage, fracture, absorption, or subsidence<sup>8</sup>. Failure of the graft for any reason usually was associated with a deformity, which was more severe than it would have been with conservative therapy, because debridement of the focus of the disease had resulted in a larger deficit of the anterior column<sup>8</sup>. The level of the lesion and the length of the grafts were the main determining factors in the outcome of surgery. Failure of the grafts occurred more frequently in the dorsal and dorsolumbar regions, probably because of the increased mechanical stress of the kyphosis in the dorsal region and the instability associated with the transitional zone of the dorsolumbar

region. The length of the graft also played a crucial role because the rate of favourable results was 85% when the graft spanned only one disc space; 60% when the graft spanned two disc spaces; 35% when it spanned three disc spaces, and 0% when it spanned four disc spaces<sup>8,15</sup>. Similar results have been reported by Bailey et al<sup>15</sup> who reported a high rate of failure of the grafts in patients with destruction of more than two vertebrae. It is clear that anterior strut bone grafts should be supplemented by posterior fusion and instrumentation to prevent progression of kyphosis in patients with severe disease. The initial phobia of using metals in the presence of infection is unfounded and it is current surgical practice to use instrumentation freely to provide stability to aid fusion and prevent progressive collapse.

#### **Established Deformity: Surgical options**

Surgery for established deformity has unacceptable rate of neurologic complications<sup>2,4,5</sup>. Sequential procedure, which involves the stages of fitting of the halo-pelvic distraction apparatus, anterior spinal osteotomy and decompression of the spinal cord, slow and gradual spinal distraction, posterior osteotomy and fusion, additional spinal distraction, and anterior spine fusion after maximum correction is gaining popularity<sup>4</sup>. Yau et al reported 10% mortality rate after this procedure.

Therefore, this surgery is advocated only in patients in whom the deformity is severe, active disease still is present, and paraplegia or death from chest complications is imminent<sup>5</sup>. In patients with healed disease in whom the dangers of paraplegia and rapid progression of the deformity are less, the hazards of treatment would seem to outweigh the gains.

## REFERENCES

1. Tuli SM. Severe kyphotic deformity in tuberculosis of the spine. *Int Orthop*. 1995;327–31.
2. Moon MS, Lee MK. The changes of the kyphosis of the tuberculous spine in children following ambulant treatment. *Korean Orthop Assoc*. 1991;(6):203–8.
3. Parathasarathy R, Sriram K, Santha T, Prabhakar R, Somasundaram PR, Sivasubramanian S. Short course chemotherapy for tuberculosis of the spine: A comparison between ambulant treatment and radical surgery: Ten year report. *J Bone Joint Surg*. 1999;81(B):464–4.
4. Yau ACMC, Hsu LCS, O'Brien JP, Hodgson AR: Tuberculosis kyphosis-correction with spinal osteotomy, halo-pelvic distraction and anterior and posterior fusion. *J Bone Joint Surg*. 1974;56(A):1419–34.
5. Rajasekaran S. The Problem of Deformity in Spinal Tuberculosis. *Clin Orthop Relat Res*. 2002;85-92.
6. Rajasekaran S, Shanmugasundaram TK, Dheenadhayalan J, Shetty DK. Tuberculosis lesions of the lumbosacral region: A 15 year follow up of patients treated by ambulant chemotherapy. *Spine*. 1999;(23):1163–7.
7. Rajasekaran S. A longitudinal study on the progress of deformity in children with spinal tuberculosis [PhD Thesis]. Chennai, India: Dr. MGR Medical University; 1999.
8. Rajasekaran S, Soundarapandian S. Progression of kyphosis in tuberculosis of the spine treated by anterior arthrodesis. *J Bone Joint Surg*. 1989;71(A):1314–23.
9. Rajasekaran S. The natural history of post-tubercular kyphosis in children: Radiological signs which predict late increase in deformity. *J Bone Joint Surg*. 2001;83(B):954–62.
10. Puig Guri J. The formation and significance of vertebral ankylosis in tuberculous spines. *J Bone Joint Surg*. 1947;29:136–48.
11. Rajasekaran S, Shanmugasundaram TK. Prediction of the angle of gibbus deformity in tuberculosis of the spine. *J Bone Joint Surg*. 1987;69(A):503–9.
12. Upadhyay SS, Saji MJ, Sell P, Yau AIMC. The effect of age on the change in deformity after radical resection and anterior arthrodesis for tuberculosis of the spine. *J Bone Joint Surg*. 1994;76(A):701–8.
13. Hodgson AR, Stock FE. Anterior spinal fusion for the treatment of tuberculosis of the spine. *J Bone Joint Surg*. 1960;42(A):295–310.
14. Medical Research Council. A 10 years assessment of a controlled trial comparing debridement and anterior spinal fusion in the management of tuberculosis of the spine in patients on standard chemotherapy in Hong Kong: VIII report. *J Bone Joint Surg*. 1982;64(B):393–8.
15. Bailey HL, Gabriel M, Hodgson AR, Shin JS. Tuberculosis of the spine in children: Operative findings and results in one hundred consecutive patients treated by removal of the lesion and anterior grafting. *J Bone Joint Surg*. 1972;54(A):1633–57.
16. Moon MS, Woo YK, Lee KS, Ha KY, Kim SS, Sun DH, et al. Posterior instrumentation and anterior interbody fusion for tuberculous kyphosis of dorsal and lumbar spines. *Spine*. 1995;(20):1910–6.

## CONCLUSION

The kyphotic deformity is the most neglected aspect of Pott's spine during the course of treatment. Children have greater degree of deformity at presentation and higher chance of progression in the future. Since surgery for established deformity is hazardous and difficult, the preventive measures carry lot of significance.