

Case report on Tuberous Sclerosis

Shrestha S¹, Shrestha S², Ojha AR³

¹Sushma Shrestha, ²Sabina Shrestha, Residents; ³Anil Raj Ojha, Assistant Professor; Department of Paediatrics, Kathmandu Medical College Teaching Hospital, Kathmandu, Nepal.

ABSTRACT

Tuberous Sclerosis Complex is a rare genetic disorder inherited in autosomal dominant fashion. It is a multisystem disorder involving brain, skin, kidneys, heart, eyes and lungs which becomes apparent only in late childhood, limiting the usefulness of early diagnosis in infancy. Here, we report a case of an 11 year male child with tuberous sclerosis.

Key words: Adenoma sebaceum, Seizure, Shagreen patch, Tuberous sclerosis

INTRODUCTION

Tuberous sclerosis complex (TSC) or Bourneville's disease, first described by Desiree- Magloire Bourneville in 1880, is a rare genetic disorder of autosomal dominant inheritance with the prevalence of one in 6000 live birth, affecting both sexes and all ethnic groups^{1,2}. It is a multisystem disorder involving brain, skin, kidneys, heart, eyes, and lungs which becomes apparent only in late childhood, limiting the usefulness for early diagnosis in infancy.

CASE REPORT

An 11 year old male child from Pulchowk, Lalitpur presented to the Emergency Department of Kathmandu Medical College Teaching Hospital with history of multiple episodes of generalized tonic-clonic seizure for the last 10 days. In past, he had multiple hospital admissions for the same reason and was on antiepileptic drug since the age of one year with poor control. He was born of non-consanguineous marriage with uneventful birth history. There was no history of seizure in family members; however his father had skin nodules over the face and neck along with a hypopigmented macule over the trunk.

On detailed examination, the child was malnourished (Protein energy malnutrition Grade II as per Indian Academy of Paediatrics Classification based on weight for age) with Tanner stage I of physical development. The child had multiple hyper-pigmented papules over the nasolabial region (adenoma sebaceum). He also had multiple (five) hypo-pigmented macules (ash leaf) over the lower limbs along with a Shagreen patch over the lateral aspect of the left buttock. Detailed CNS examination revealed increased tone of both upper and lower limbs with brisk deep tendon reflexes and bilateral positive Babinski's sign but absent superficial reflexes. Other systemic examination and fundus examination revealed no abnormality.

Investigations showed sub ependymal nodules in computed tomography (CT) scan of head, other test like haemoglobin, complete blood count, renal and liver function tests were normal. His serum carbamazepine level was within therapeutic range. However, the serum valproate level was way below the therapeutic range. During the hospital stay the dose of sodium valproate was increased after which the seizure frequency decreased though he had short seizures in-between.

DISCUSSION

Tuberous sclerosis complex (TSC) is a rare genetic disorder with heterogeneous presentation varying from severe mental retardation and incapacitating seizures to normal intelligence and an absence of seizure, often within the same family. It is due to inactivating mutation in one of the two genes, TSC1 encoding hamartin, or TSC2 encoding tuberin².

Address for correspondence

Dr. Sushma Shrestha
Resident
Department of Paediatrics
Kathmandu Medical College Teaching Hospital,
Kathmandu, Nepal
E-mail: swatzsr@yahoo.com

The major neurological manifestations of tuberous sclerosis complex are seizures, autism, developmental delay and behavioral and psychiatric disorder. Seizure is present in about 80-90% of patient which begins during the first year of life; varies from subtle focal seizure, infantile spasm, to generalized seizure^{1,3}. Seizures are managed with an anticonvulsant medication like Vigabatrin (infantile spasm), Lamotrigine (generalized seizure)². But young children with TSC who have early onset of focal seizure or spasm, develops intractable seizure later that responds poorly to antiepileptic drug¹. Those are candidates for alternative non-pharmacological treatment which includes vagus nerve stimulation, use of ketogenic diet, and resective epileptic surgery⁴.

TSC has dermatologic manifestations like hypomelanotic macule(90%), facial angiofibromas (75%), Shagreen patch (20-30%)². Hypomelanotic macules are present at birth and almost all lesions are evident within the first two years of life. Facial angiofibromas (adenoma sebaceum) are present during preschool years in the malar area as small pink to red dome-shaped papules in a "butterfly distribution". The shagreen patch is found in the lumbosacral region characteristically present

as an irregularly shaped roughened raised lesion with orange peel consistency. Adolescent pediatric children may have cosmetic issues, so recent trial support the use of topical 0.1% Rapamycin on facial angiofibromas⁵. Use of Inhibitors of the mammalian target of rapamycin (mTOR) in regression of astrocytomas, angiofibromas and angiomyolipomas are newer modalities in the management of tuberous sclerosis⁶.

Diagnostic Criteria⁷ for TSC is as given in the table below. Definite TSC can be made when two major or one major plus two minor features are demonstrated.

Our patient had four major criteria (subependymal nodules in CT scan head, facial angiofibroma, hypomelanotic macules more than three in number, Shagreen patch) which fit in the diagnosis of Tuberous sclerosis. He had intractable seizure needing frequent adjustment of antiepileptic drug. During this admission, dose of antiepileptic drug (sodium valproate and carbamazepine) was adjusted accordingly with control of seizure. As we know Tuberous sclerosis is a rare genetic disorder, so late diagnosis is very common in our part of world due to the paucity of facilities.

Table. 1: Major and Minor Criteria of tuberous sclerosis complex

Major Criteria	Minor Criteria
1. Cortical tuber	1. Cerebral white matter migration lines
2. Subependymal nodule	2. Multiple dental pits
3. Facial angiofibroma or forehead plaque	3. Gingival fibromas
4. Ungual or periungual fibroma (nontraumatic)	4. Bone cysts
5. Hypomelanotic macules (>3)	5. Retinal achromatic patch
6. Shagreen patch	6. Confetti skin lesions
7. Multiple retinal hamartomas	7. Nonrenal hamartomas
8. Cardiac rhabdomyoma	8. Multiple renal cysts
9. Renal angiomyolipoma	9. Hamaromatous rectal polyps
10. Pulmonary lymphangioleiomyomatosis	

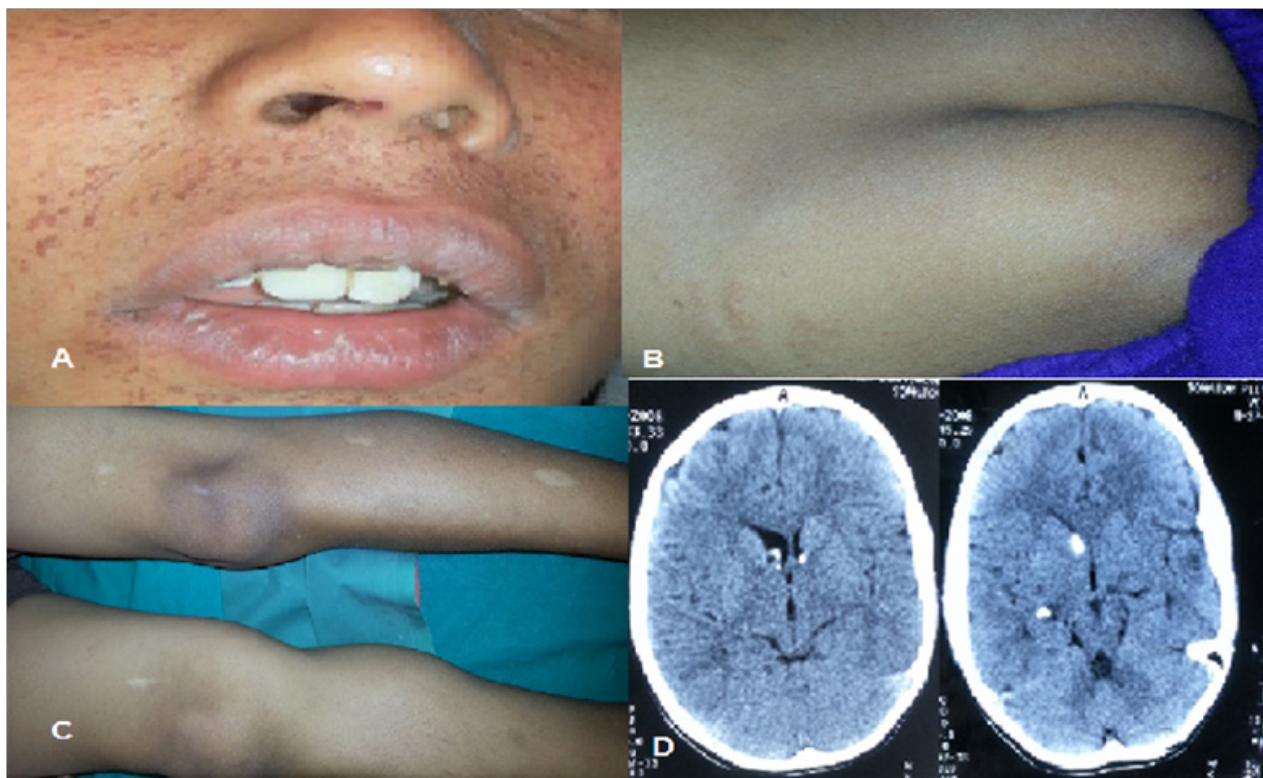


Figure 1: Features of Tuberous Sclerosis in the patient. Adenoma sebaceum (A). Shagreen patch (B). Hypomelanotic patch more than three in number (C). CT scan of head showing subependymal nodule (D).

CONCLUSION

TSC is one of the neurocutaneous syndromes inherited in autosomal dominant fashion with almost complete penetrance with variable expressivity, affecting almost all organs. The quality of life depends on the neurological

manifestation like seizures and mental retardation which is improved by multidisciplinary approach and symptomatic organ specific treatment. Clinical diagnosis complementing with DNA testing allows precise genetic counseling, which is important.

REFERENCES

- 1 Curatolo P, Maria BL. Tuberous sclerosis. In: Dulac O, Lasonade M, Sarnat HB, editors. Pediatric Neurology part I. Elsevier B.V; 2013. P.323-31. (Handbooks of Clinical Neurology; volume 111).
- 2 Leung AKC, Robson LM. Tuberous Sclerosis Complex: A Review. J Pediatr Health Care. 2007; 21:108-114.
- 3 Finkelstein R. Advances in Tuberous Sclerosis Complex Research: The October 1, 2003, Child Neurology Society Workshop. J Child Neurol. 2004; 19:734.
- 4 Thiele EA. Managing Epilepsy in Tuberous Sclerosis Complex. J Child Neurol 2004;19:734.
- 5 Madke B. Indian Dermatol Online J. 2013; 4(1):54-57.doi: 10.4103/2229-5178.105488.
- 6 Krueger DA, Franz DN. Current Management of Tuberous Sclerosis Complex. Pediatr Drugs. 2008;10(5):299-313.
- 7 Sahin M. Tuberous sclerosis. In: Kliegman RM, Stanton BF, Geme III JWS, Schor NF, Behrman RE, editors. Nelson Textbook of Pediatrics. 19th ed. Philadelphia: Elsevier;2011.